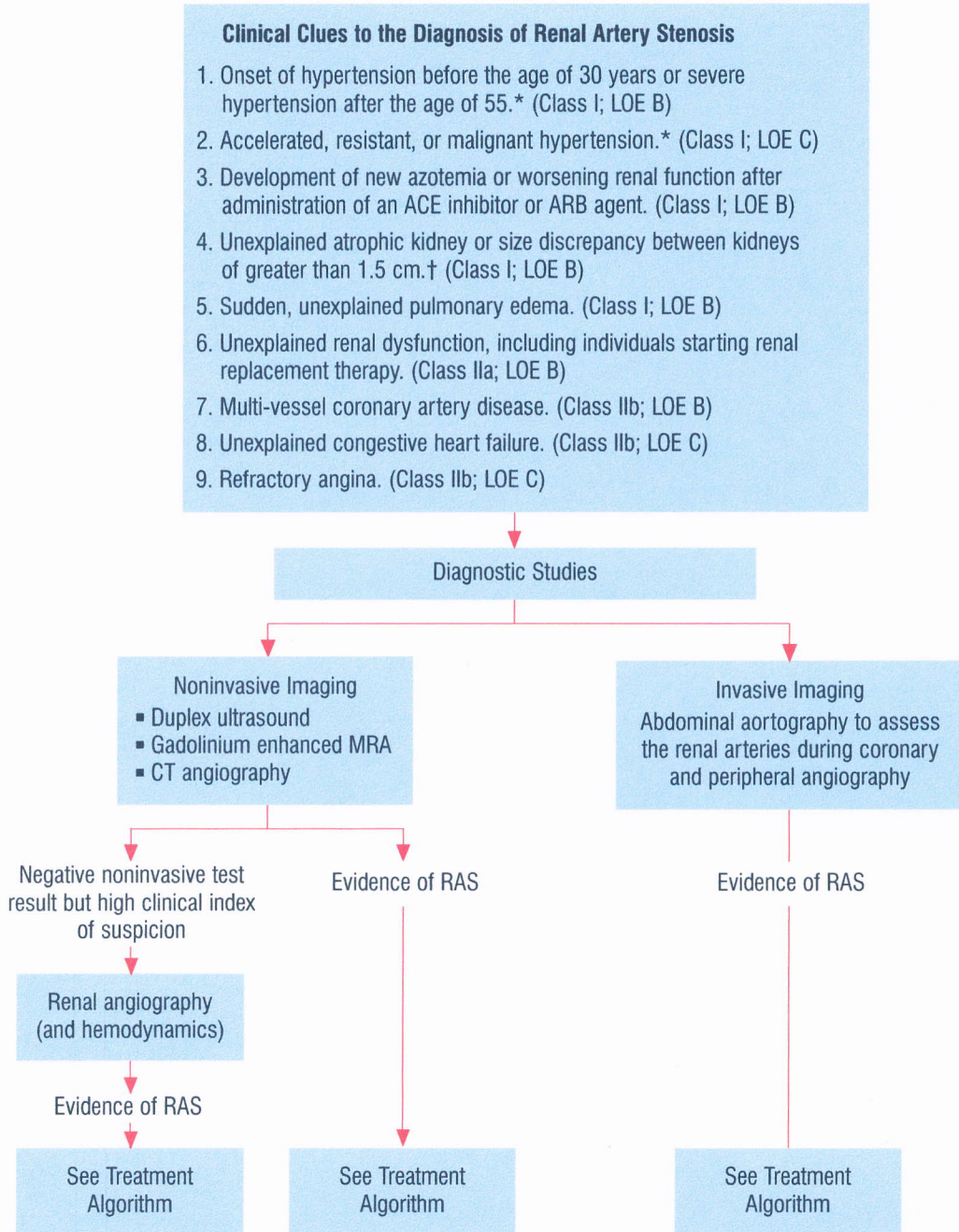


Figure 9. Clinical Clues to the Diagnosis of Renal Artery Stenosis



*For definition of hypertension, please see Chobanian AV, Bakris GL, Black HR, et al. The Seventh Report of the Joint National Committee on Prevention, Detection, Evaluation, and Treatment of High Blood Pressure: the JNC 7 report. JAMA 2003; 289:2560-72.

†For example, atrophic kidney due to chronic pyelonephritis is not an indication for renal artery stenosis (RAS) evaluation.

ACE = angiotensin-converting enzyme; **ARB** = angiotensin receptor blocking agent; **CT** = computed tomography; **LOE** = level of evidence; **MRA** = magnetic resonance angiography.